

# Diaphragmatic Reinnervation in Ventilator-Dependent Patients with Cervical Spinal Cord Injury and Concomitant Phrenic Nerve Lesions Using Simultaneous Nerve Transfers and Implantable Neurostimulators

Matthew R. Kaufman, MD<sup>1,2,3</sup> Andrew I. Elkwood, MD<sup>1,2</sup> Farid Aboharb, BA<sup>2</sup> John Cece, BA<sup>2</sup>  
David Brown, DO<sup>4</sup> Kameron Rezzadeh, BA<sup>3</sup> Reza Jarrahy, MD<sup>3</sup>

<sup>1</sup>The Center for Treatment of Paralysis and Reconstructive Nerve Surgery, Jersey Shore University Medical Center, Neptune, New Jersey

<sup>2</sup>The Institute for Advanced Reconstruction, Shrewsbury, New Jersey

<sup>3</sup>Division of Plastic and Reconstructive Surgery, David Geffen UCLA Medical Center, Los Angeles, California

<sup>4</sup>Department of Rehabilitative Medicine, JFK Johnson Rehabilitation Institute, Edison, New Jersey

Address for correspondence Matthew R. Kaufman, MD, The Institute for Advanced Reconstruction, 535 Sycamore Avenue, Shrewsbury, NJ 07702 (e-mail: kaufmanmatthew@hotmail.com).

J Reconstr Microsurg

## Abstract

**Background** Patients who are ventilator dependent as a result of combined cervical spinal cord injury and phrenic nerve lesions are generally considered to be unsuitable candidates for diaphragmatic pacing due to loss of phrenic nerve integrity and denervation of the diaphragm. There is limited data regarding efficacy of simultaneous nerve transfers and diaphragmatic pacemakers in the treatment of this patient population.

**Methods** A retrospective review was conducted of 14 consecutive patients with combined lesions of the cervical spinal cord and phrenic nerves, and with complete ventilator dependence, who were treated with simultaneous microsurgical nerve transfer and implantation of diaphragmatic pacemakers. Parameters of interest included time to recovery of diaphragm electromyographic activity, average time pacing without the ventilator, and percent reduction in ventilator dependence.

**Results** Recovery of diaphragm electromyographic activity was demonstrated in 13 of 14 (93%) patients. Eight of these 13 (62%) patients achieved sustainable periods (>1 h/d) of ventilator weaning (mean = 10 h/d [ $n = 8$ ]). Two patients recovered voluntary control of diaphragmatic activity and regained the capacity for spontaneous respiration. The one patient who did not exhibit diaphragmatic reinnervation remains within 12 months of initial treatment. Surgical intervention resulted in a 25% reduction ( $p < 0.05$ ) in ventilator dependency.

**Conclusion** We have demonstrated that simultaneous nerve transfers and pacemaker implantation can result in reinnervation of the diaphragm and lead to successful ventilator weaning. Our favorable outcomes support consideration of this surgical method for appropriate patients who would otherwise have no alternative therapy to achieve sustained periods of ventilator independence.

## Keywords

- ▶ diaphragmatic paralysis
- ▶ implantable neurostimulator
- ▶ phrenic nerve
- ▶ quadriplegia
- ▶ ventilator weaning

received  
November 4, 2014  
accepted after revision  
February 1, 2015

Copyright © by Thieme Medical Publishers, Inc., 333 Seventh Avenue, New York, NY 10001, USA.  
Tel: +1(212) 584-4662.

DOI <http://dx.doi.org/10.1055/s-0035-1549159>.  
ISSN 0743-684X.

High spinal cord lesions in tetraplegic patients commonly impede conduction of nerve impulses from the central nervous system to peripheral nerves and target muscles, including the diaphragm. Respiratory insufficiency resulting from cervical tetraplegia often leads to chronic ventilator dependence, an expensive management strategy associated with significant morbidity and mortality.<sup>1,2</sup> When phrenic nerve integrity is preserved, phrenic nerve or diaphragmatic pacemakers can be used to gradually wean patients from mechanical ventilation. Successful diaphragmatic pacing in spinal cord injury has been associated with quality of life improvements as a result of enhanced eating, speaking, and overall mobility.<sup>3,4</sup> Unfortunately, implanted pacemakers fail to elicit diaphragmatic contraction when there is Wallerian degeneration of the phrenic nerves, a phenomenon that occurs when the level of spinal cord injury partially or completely encompasses the phrenic nerve roots at C3–C5.

Patients with high cervical tetraplegia often have combined spinal cord and peripheral nerve lesions, both of which must be overcome to achieve successful ventilator weaning. Restoration of phrenic nerve integrity and subsequent reinnervation of each hemi-diaphragm will allow pacemakers to adequately stimulate muscle and therefore improve respiratory function. Krieger and Krieger first reported the feasibility of simultaneous nerve transfers and pacemaker placement to reverse ventilator dependency in tetraplegics with concomitant lesions.<sup>5</sup> Combined bilateral intercostal nerve transfers with pacemakers were performed in 10 patients, and led to reinnervation of the diaphragm and successful ventilator weaning. In this study, we describe our experience with simultaneous pacemaker implantation and nerve transfers in 14 patients to further demonstrate the efficacy and safety of this procedure for appropriately selected ventilator-dependent cervical tetraplegics. In addition, we propose a preoperative assessment that includes consideration of possible nerve transfers to prevent failed or aborted pacemaker-only procedures in patients who require a dual approach.

## Materials and Methods

Following the approval of our institutional review board, we retrospectively reviewed the treatment of 14 consecutive ventilator-dependent patients with high cervical tetraplegia (C1–C4) cared for at two tertiary referral centers (Center for the Treatment of Paralysis and Reconstructive Nerve Surgery, Jersey Shore University Medical Center, Neptune, New Jersey and David Geffen UCLA Medical Center, Los Angeles, California) between December 2010 and November 2013. The study group was part of a larger cohort of patients evaluated for diaphragmatic pacemaker implantation and selected based upon preoperative electrodiagnostic testing that revealed absence of phrenic nerve conduction and diaphragm electromyographic activity, consistent with combined cervical spinal cord injury and phrenic nerve lesions.

Criteria for inclusion in the study included presence of cervical tetraplegia, chronic ventilator dependence (> 6 months), an electrodiagnostic exam revealing absence of both phrenic nerve conduction and diaphragm electro-

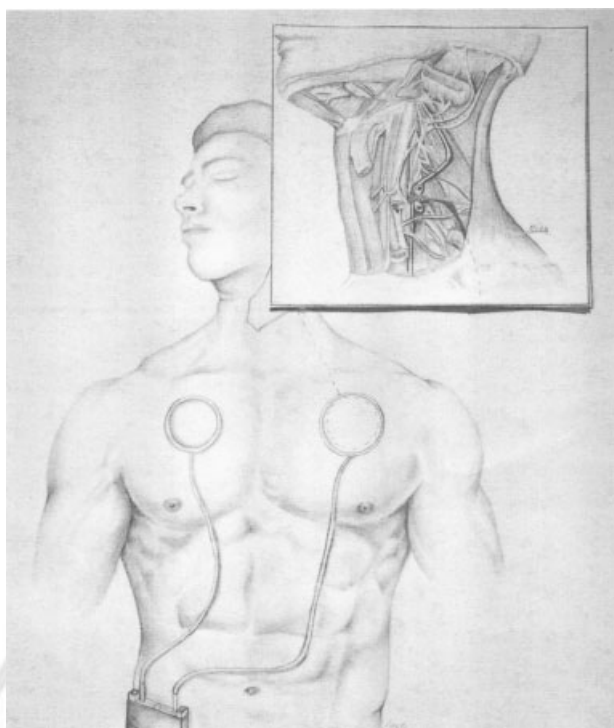
myographic activity (and/or a prior failed pacemaker placement attempt), absence of active respiratory infection, good cognitive function, and adequate family/nursing supportive care. All patients underwent preoperative electrodiagnostic testing (electromyography [EMG] and nerve conduction studies [NCS]) of the phrenic nerve and diaphragm, as well as assessment of potential donor nerves in the neck and chest (i.e., spinal accessory, intercostal, thoracodorsal). When preoperative EMG/NCS testing indicated complete or partial denervation of the spinal accessory nerve(s), the intercostal (or thoracodorsal) nerves were selected for transfer. Otherwise, the less invasive nature of the cervical approach in accessing both the phrenic and spinal accessory nerves was the basis for offering this method.

Surgical treatment consisted of simultaneous bilateral nerve transfers, performed in the cervical or thoracic regions, and implantation of diaphragmatic pacemakers (Avery Biomedical, Commack, New York). Intraoperative nerve testing was utilized to confirm absence of phrenic nerve/diaphragmatic function and to retest donor nerves prior to transfer. The thoracic approach involved an anterolateral thoracotomy incision at the eighth or ninth intercostal space. The subjacent, laterally based intercostal nerve pedicle graft was elevated and the thoracic cavity entered. The distal 15 cm of phrenic nerve was isolated for proximal neurectomy and transposition toward the chest wall. An end-to-end neural microanastomosis was performed between the intercostal and phrenic nerves. The electrode end of the pacemaker was looped around the phrenic nerve distal to neural coaptation and secured. The pacemaker receiver was buried in a deep subcutaneous space inferomedial to the thoracotomy incision. The cervical approach involved a supraclavicular incision to identify both the phrenic and spinal accessory nerves. An end-to-end neural microanastomosis was performed between these two structures, and the electrode end of the pacemaker was looped around the phrenic nerve distal to the anastomosis. The pacemaker receiver was buried in a deep subcutaneous pocket in the upper chest (► Fig. 1).

Transtelephonic electromyographic monitoring (TTM) was performed bimonthly during the follow-up period to evaluate recovery of diaphragmatic activity.<sup>6</sup> Parameters for assessment included age, sex, level of injury, American Spinal Injury Association (ASIA) classification, time from injury to treatment (months), time from surgery to TTM activity (months), average time (h) pacing, and percent reduction in ventilator dependency.

## Results

Eleven males and three females were treated. The median age of patients treated was 27 years (range = 10–66 years). There were two patients each who had C1, C2, and C4 tetraplegia and one patient who suffered from a C3-level injury (► Table 1). The remaining seven patients had multilevel cervical injuries. Thirteen patients were classified as ASIA A (complete absence of sensorimotor function below level of injury). One patient was classified as ASIA B (sensory but not motor function is preserved below the level of injury).



**Fig. 1** Schematic illustrating cervical approach for simultaneous neurotization (between phrenic and spinal accessory nerves) and implantation of diaphragmatic pacemaker.

Median duration between onset of injury and surgical intervention was 21 months (range: 6–90). Eight patients (57%) had undergone prior attempts at laparoscopic placement of a diaphragmatic pacemaker that were aborted intraoperatively due to failure to achieve diaphragmatic stimulation.

Seven patients underwent simultaneous nerve transfer and pacemaker placement using a cervical approach, whereas a thoracic approach was used in eight patients. One patient underwent surgery using both cervical and thoracic approaches. The spinal accessory and intercostal nerves (eighth or ninth) were each utilized for nerve transfer in seven patients, respectively. The thoracodorsal nerves were transferred in one patient (► **Table 1**).

In 13 patients (93%), reinnervation of the diaphragm was demonstrated by recovery of biphasic activity on postoperative TTM (► **Fig. 2**). Median time from surgical intervention until recovery of diaphragmatic activity was 6 months (range: 3–18 months). Eight of these 13 (62%) patients achieved sustainable periods of ventilator weaning (>1 h/d). The average time pacing without the ventilator as of most recent follow-up was 10 hours (range: 3–24 h/d [ $n = 8$ ]). Two patients recovered voluntary control of diaphragmatic activity and regained the capacity for spontaneous respiration without the pacemaker (patients 4 and 7). There was an overall 25% ( $p < 0.05$ ) reduction in ventilator dependency following surgical intervention in the study group.

Diaphragmatic reinnervation without sustainable ventilator weaning (<1 h/d) was observed in five patients, three of whom had periods of follow-up longer than 12 months. An additional patient (patient 13), who has not yet exhibited

diaphragmatic reinnervation, remains within 12 months of initial treatment. There were no intraoperative complications. One patient developed bilateral pleural effusions postoperatively that required drainage. Three patients required revision surgery to replace and/or reposition malfunctioning pacemaker receivers. Subsequent to our most recent data analysis, one patient expired from cardiac arrest (patient 4) and another stopped pacing altogether secondary to severe depression while going through a divorce (patient 8). Median follow-up in this patient population was 13 months (range: 5–40).

## Discussion

Cervical tetraplegia is a debilitating condition with associated functional limitations, which are often profound. Loss of spontaneous respiratory activity with resulting chronic ventilator dependence negatively impacts both quality of life and overall morbidity and mortality within this patient population.<sup>1</sup> Despite advancements in the medical management of ventilator-dependent patients, many patients will never regain spontaneous respiratory function.<sup>7,8</sup> In this study, we have demonstrated that simultaneous nerve transfers and pacemaker implantation can result in both diaphragmatic reinnervation and sustained periods of ventilator weaning in patients who were previously completely ventilator dependent. Diaphragmatic pacemakers have been utilized for more than 25 years to reverse ventilator dependence in cervical spinal cord injury with reported success rates of 80% or greater.<sup>9,10</sup> The requirements for successful pacing include a motivated patient and caregiver, absence of active pulmonary infection, and maintenance of phrenic nerve integrity.<sup>11</sup>

Our findings are consistent with prior work presented by Krieger and Krieger, the first to demonstrate the safety and feasibility of this dual procedure. The successful application of neurotization to reverse diaphragm paralysis in spinal cord injury is consistent with its use in peripheral nerve repair, whereby a degenerated nerve can recover axonal integrity by linking a functioning (or stimulatable) nerve donor.<sup>12</sup> Following a period of time required for regeneration, the target muscle may recover functional activity. In patients with isolated peripheral nerve injuries, the result is recovery of independent function, whereas in the cervical spinal cord injury patient, peripheral nerve regeneration will typically result in the ability to use electrical stimulation to restore muscle activity. Recovery of independent activity is also possible when the donor nerve emerges from the spinal cord above the level of neurological injury (patients 4 and 7). Both of these patients were able to spend long periods (24 and 12 hours, respectively) free of the ventilator, either breathing completely independently or using the pacemaker.

Although nerve regeneration following nerve transfer may fail to occur, success rates approaching 90% have been reported in the upper and lower extremities.<sup>13–15</sup> Successful nerve regeneration is often associated with the following favorable prognostic factors: young age, more recent injury, meticulous surgical technique, and comprehensive rehabilitation.<sup>16–18</sup> In our own series, it does appear that patients with more recent

**Table 1** Demographic data of study group undergoing simultaneous nerve transfers and pacemaker placement to reverse ventilator dependency

Patient	Age	Sex	Level	ASIA	Prior PA	Donor Nerve	I-S (mo)	S-R (mo)	Pacing (h)	F/U (mo)
1	23	M	C1–C4	A	N	IC	40	18	<1	23
2	22	M	C1	A	N	IC	12	7	–	24
3	39	M	C4	A	N	SA	90	6	24	24
4	63	M	C2–C5	B	N	SA	22	9	24 <sup>a</sup>	40
5	26	M	C3	A	Y	IC	84	3	<1	19
6	66	M	C4	A	Y	SA	6	6	4	13
7	28	M	C2	A	N	SA	20	3	12 <sup>a</sup>	9
8	33	M	C1	A	Y	IC	10	8	4	13
9	46	M	C2	A	Y	SA	16	10	3	26
10	18	M	C3–C6	A	Y	IC	18	4	6	11
11	19	F	C2–C3	A	Y	IC, SA	54	6	5	6
12	10	F	C1–C2	A	Y	SA	58	4	<1	6
13	27	M	C2–C6	A	Y	TD	10	–	–	8
14	26	F	C2–C7	A	N	IC	32	4	–	5
Median	27						21	6 ( <i>n</i> = 13)	10 <sup>b</sup> ( <i>n</i> = 8)	13

Abbreviations: IC, intercostal; I-S, time (mo) from onset of injury to surgical treatment; Prior PA, prior pacemaker placement attempted (failed or aborted); SA, spinal accessory; S-R, time (mo) from surgical treatment to diaphragmatic reinnervation (recovery of transtelephonic electromyographic monitoring activity); TD, thoracodorsal.

<sup>a</sup>Achieved spontaneous respiratory activity independent of both ventilator and pacemaker.

<sup>b</sup>Mean value.

injuries (<24 months) had a shorter regeneration period and demonstrated an easier transition from mechanical ventilation to the pacemaker. As would follow logically, we found longer intervals between injury and treatment had a negative effect on overall weaning success. Of the three patients (with greater than 12-month follow-up) who failed to achieve sustainable periods (> 1 h/d) of ventilator weaning, two had remote injuries (40 and 84 months, respectively). Prior investigation has clearly demonstrated how positive pressure ventilation requirements following cervical spinal cord injury are associated with rapid, progressive denervation muscle atrophy, a possible rationale for why older injuries may be more difficult to reverse.<sup>19</sup>

From our results, it is clear that complete recovery may occur in as early as several months, or in some cases, a year or longer. Simultaneous implantation of the pacemaker at the time of nerve transfer allows us to begin electrical stimulation prior to reinnervation, anticipating that this will expedite axonal regrowth. Both animal and human studies have indicated the utility of electrical stimulation in promoting nerve regeneration.<sup>20,21</sup> The dual procedure approach also avoids the need for a second surgery to implant the pacemaker. In light of these findings, we recommend a paradigm shift in the current management of these patients so as to minimize or eliminate occurrences of patients undergoing aborted pacemaker placement due to a failure to stimulate. Appropriate surgical management should be based upon preoperative electrodiagnostic studies (when available) to determine if a dual procedure with simultaneous nerve

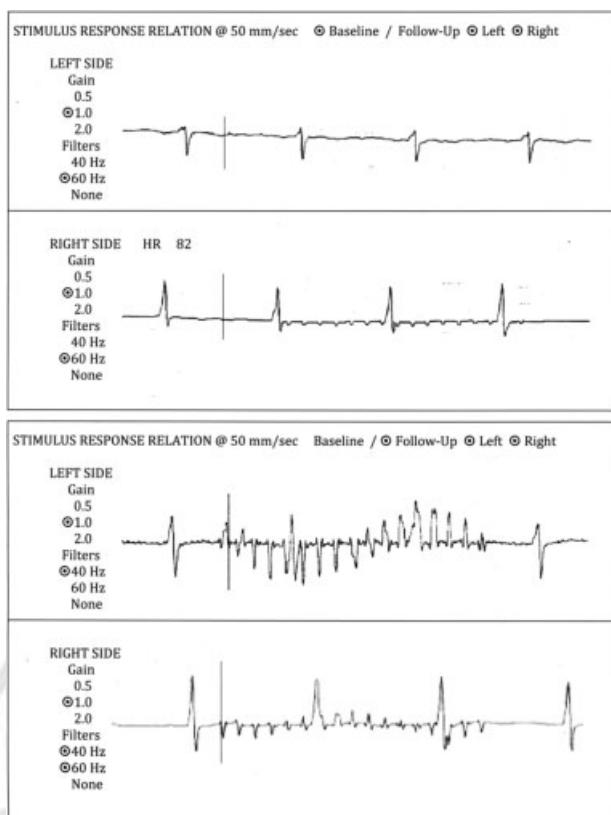
transfer and pacemaker implantation is necessary from the outset.

When preoperative electrodiagnostic testing of the phrenic nerve and diaphragm is not available, patients should be informed of the possibility of a failed procedure unless nerve transfers are simultaneously performed, and they should be allowed to make an informed decision about subsequent surgical management. Using this treatment approach, patients will be less likely to undergo inherently risky procedures that are almost certain to be unsuccessful. This improvement in informed consent will in turn limit the emotional distress associated with a failed procedure. Furthermore, it is likely that nerve regeneration and diaphragmatic recovery will be less successful the longer the delay between onset of injury and surgical treatment. It is our recommendation that patients be considered for surgical evaluation 6 to 12 months after onset of injury when there is no evidence of spontaneous weaning.

## Conclusion

We have demonstrated that simultaneous nerve transfers and pacemaker implantation in appropriately selected patients can result in diaphragmatic reinnervation and the possibility of achieving sustainable periods of ventilator weaning. Ventilator-dependent cervical tetraplegic patients who fail to wean through conservative methods should be considered for surgical intervention. Whereas diaphragm pacemakers can be effective when phrenic nerve integrity is preserved,





**Fig. 2** Interval TTM assessment performed two months (top) and nine months (bottom) following simultaneous nerve transfer and pacemaker placement (patient 4). Biphasic activity is present at the 9-month follow-up, clearly demonstrating progressive diaphragmatic reinnervation.

patients with combined lesions of the spinal cord and phrenic nerve often fail electrical stimulation.

#### Conflict of Interest

On behalf of the corresponding author and all co-authors, there is no conflict of interest.

#### References

- van den Berg ME, Castellote JM, de Pedro-Cuesta J, Mahillo-Fernandez I. Survival after spinal cord injury: a systematic review. *J Neurotrauma* 2010;27(8):1517–1528
- Berkowitz M. *Spinal Cord Injury: An Analysis of Medical and Social Costs*. New York: Demos Medical Publishing; 1998
- Fodstad H, Blom S, Linderholm H. Artificial respiration by phrenic nerve stimulation (diaphragm pacing) in patients with cervical cord and brain stem lesions. *Scand J Rehabil Med* 1983;15(4):173–181
- Adler D, Gonzalez-Bermejo J, Duguet A, et al. Diaphragm pacing restores olfaction in tetraplegia. *Eur Respir J* 2009;34(2):365–370
- Krieger LM, Krieger AJ. The intercostal to phrenic nerve transfer: an effective means of reanimating the diaphragm in patients with high cervical spine injury. *Plast Reconstr Surg* 2000;105(4):1255–1261
- Auerbach AA, Dobelle WH. Transtelephonic monitoring of patients with implanted neurostimulators. *Lancet* 1987;1(8526):224–225
- Girard TD, Kress JP, Fuchs BD, et al. Efficacy and safety of a paired sedation and ventilator weaning protocol for mechanically ventilated patients in intensive care (Awakening and Breathing Controlled trial): a randomised controlled trial. *Lancet* 2008;371(9607):126–134
- Ely EW, Bennett PA, Bowton DL, Murphy SM, Florance AM, Haponik EF. Large scale implementation of a respiratory therapist-driven protocol for ventilator weaning. *Am J Respir Crit Care Med* 1999;159(2):439–446
- Sandra Stuban R. The latest facts about the diaphragm pacing stimulation (DPS) system. *Ventilator-Assisted Living*. 2006;20(3):2–3
- Merrell GA, Barrie KA, Katz DL, Wolfe SW. Results of nerve transfer techniques for restoration of shoulder and elbow function in the context of a meta-analysis of the English literature. *J Hand Surg Am* 2001;26(2):303–314
- Ducko CT. Clinical advances in diaphragm pacing. *Innovations (Phila)* 2011;6(5):289–297
- Tung TH, Mackinnon SE. Nerve transfers: indications, techniques, and outcomes. *J Hand Surg Am* 2010;35(2):332–341
- Midha R. Nerve transfers for severe brachial plexus injuries: a review. *Neurosurg Focus* 2004;16(5):E5
- Mackinnon SE, Novak CB. Nerve transfers. New options for reconstruction following nerve injury. *Hand Clin* 1999;15(4):643–666, ix
- Tung TH, Mackinnon SE. Nerve transfers: indications, techniques, and outcomes. *J Hand Surg Am* 2010;35(2):332–341
- Gu YD, Chen DS, Zhang GM, et al. Long-term functional results of contralateral C7 transfer. *J Reconstr Microsurg* 1998;14(1):57–59
- Ozkan T, Ozer K, Gülgönen A. Restoration of sensibility in irreparable ulnar and median nerve lesions with use of sensory nerve transfer: long-term follow-up of 20 cases. *J Hand Surg Am* 2001;26(1):44–51
- Terzis JK, Vekris MD, Soucacos PN. Outcomes of brachial plexus reconstruction in 204 patients with devastating paralysis. *Plast Reconstr Surg* 1999;104(5):1221–1240
- Levine S, Nguyen T, Taylor N, et al. Rapid disuse atrophy of diaphragm fibers in mechanically ventilated humans. *N Engl J Med* 2008;358(13):1327–1335
- Al-Majed AA, Neumann CM, Brushart TM, Gordon T. Brief electrical stimulation promotes the speed and accuracy of motor axonal regeneration. *J Neurosci* 2000;20(7):2602–2608
- Gordon T, Brushart TM, Amirjani N, Chan KM. The potential of electrical stimulation to promote functional recovery after peripheral nerve injury—comparisons between rats and humans. In: Millesi H, Schmidhammer R, eds. *How to Improve the Results of Peripheral Nerve Surgery*. Vienna: Springer; 2007:3–11